



PRECISE DIAGNOSTICS

PRECISE DIAGNOSTICS LAB
294 New Dorp Ln
Staten Island, NY 10306
Phone: 347-861-7570
Fax: 347-861-7572

Page 1 of 2

S12-00655

PATIENT NAME

Collected Date: 6 Feb 2012

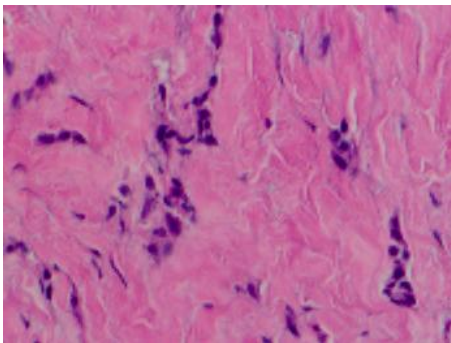
Received Date: 6 Feb 2012

Report Date: 8 Feb 2012

PATIENT INFORMATION

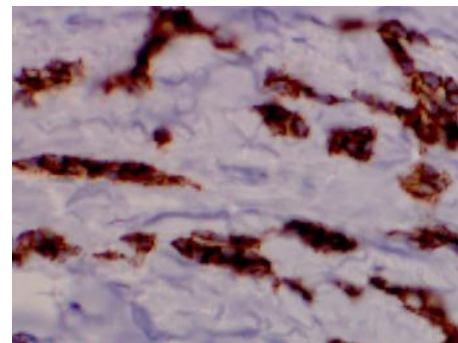
PHYSICIAN INFORMATION

IMAGE 1



Invasive Carcinoma

IMAGE 2



E-Cadherin Positive

CLINICAL HISTORY: Breast mass, r/o cancer

DIAGNOSIS:

**Left breast core biopsy, 8-9 o' clock, 12 cm from nipple: AMENDED DIAGNOSIS
Invasive mammary carcinoma with ductal and lobular features, intermediate grade**

Comment: The immunostain for E-cadherin is positive in tumor cells. The combination of E-cadherin positivity and histologic growth pattern in H & E favor the above amended diagnosis from invasive lobular carcinoma to invasive mammary carcinoma with ductal and lobular features.

AH:RD

The attending pathologist whose signature appears on this report has reviewed the diagnostic slides, and has edited the gross and microscopic portions of the report in rendering the final diagnosis.

GROSS DESCRIPTION:

Left breast core biopsy, 8-9 o' clock, 12 cm from nipple: Received in formalin, labeled with the patient's name, and "breast core biopsy" are four strips/irregularly shaped fragments of soft/friable fibroadipose tissue measuring 1.0 x 0.5 x 0.4 cm in aggregate.



PRECISE DIAGNOSTICS

PRECISE DIAGNOSTICS LAB
294 New Dorp Ln
Staten Island, NY 10306
Phone: 347-861-7570
Fax: 347-861-7572

Page 2 of 2

S12-00655

PATIENT NAME

Collected Date: 6 Feb 2012

Received Date: 6 Feb 2012

Report Date: 8 Feb 2012

PATIENT INFORMATION

PHYSICIAN INFORMATION

Entirely submitted in a tissue processing bag.
One block.

Addendum (2/10/2012)

Immunohistochemical Analysis of Breast Receptors

ESTROGEN RECEPTOR	POSITIVE	100%
PROGESTERONE RECEPTOR	POSITIVE	100%
HER 2Neu	NEGATIVE	(0)

CPT CODES: 88305, 88360-26 x3, 88342-26

ICD-9 CODES: 174.8